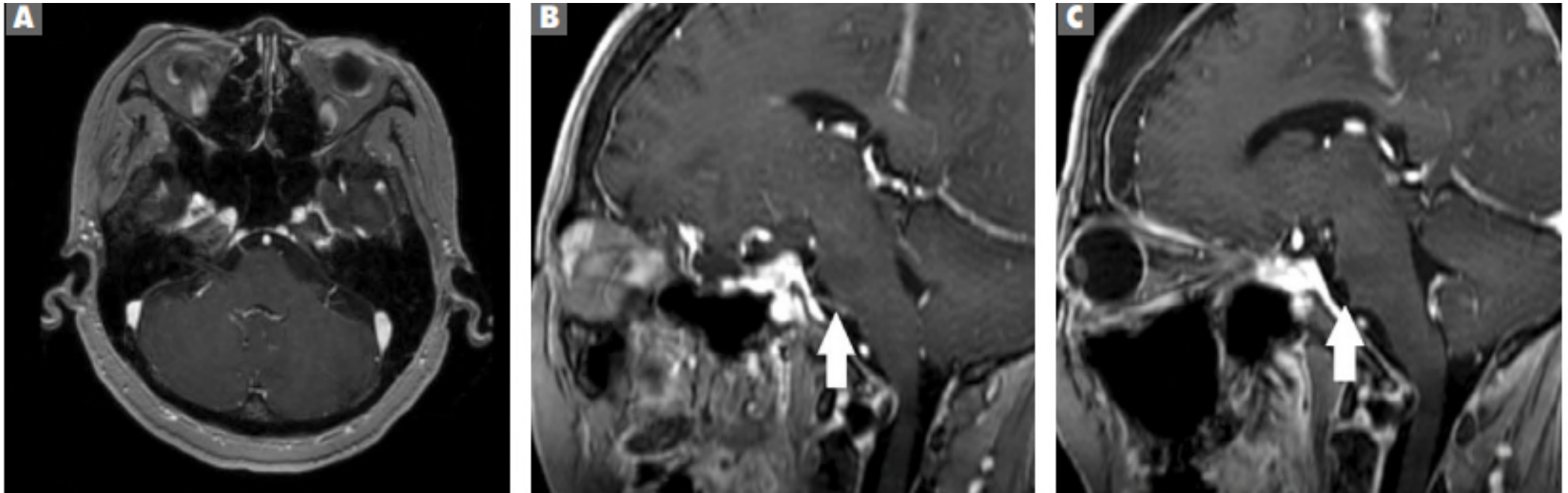
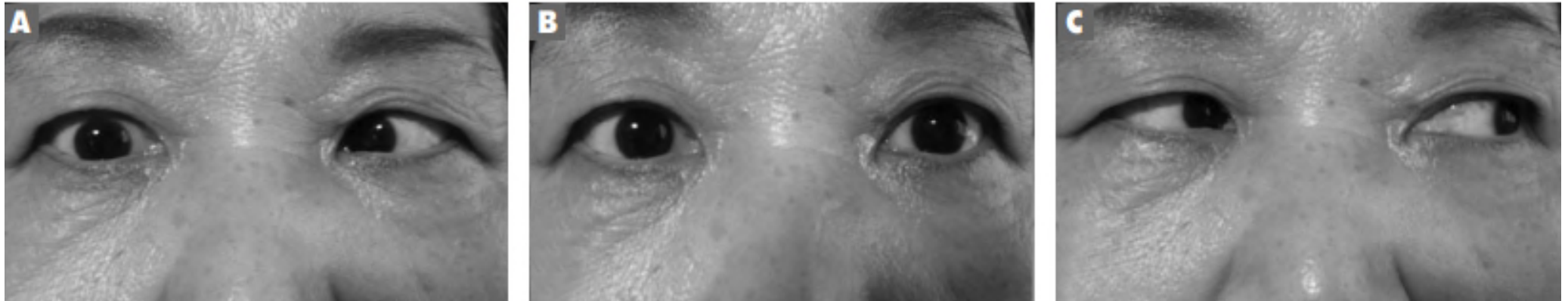


Isolated Abducens Nerve Palsy after Closed Minor Head Trauma



Axial (A) and reconstructed sagittal (B, C) magnetic resonance images demonstrate thickening and enhancement on the right abducens nerve (arrow) compared with left normal site.