

Contralateral symptom provocation after ADR

Is prophylactic surgery suitable for asymptomatic areas?

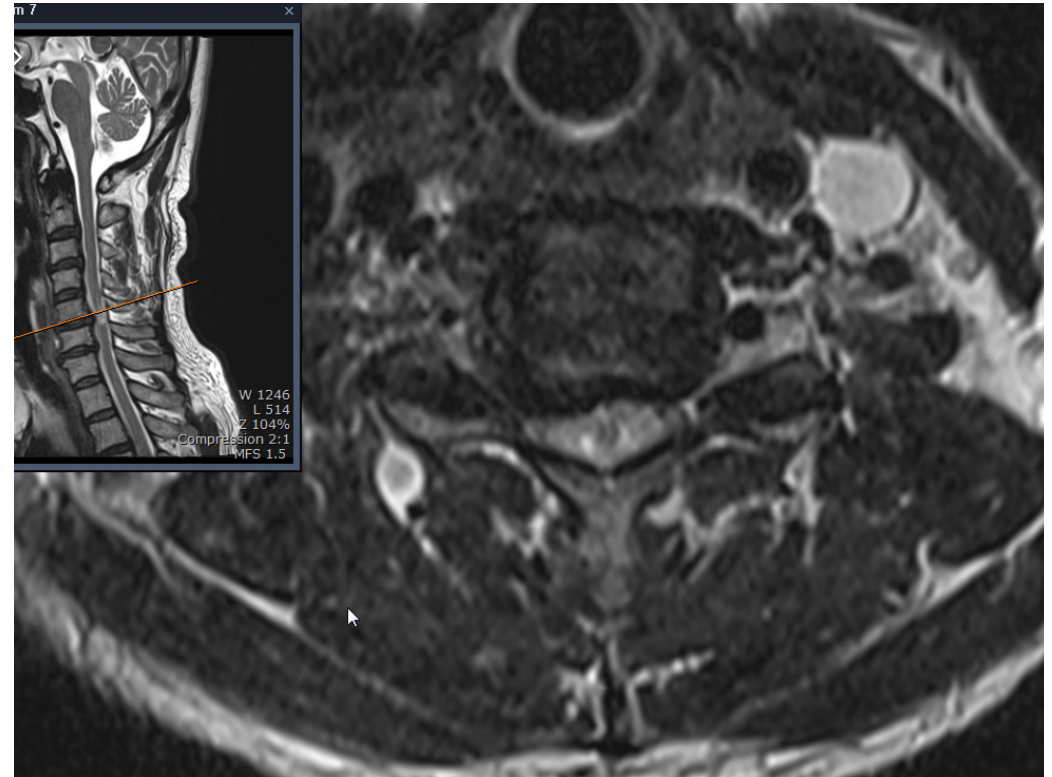
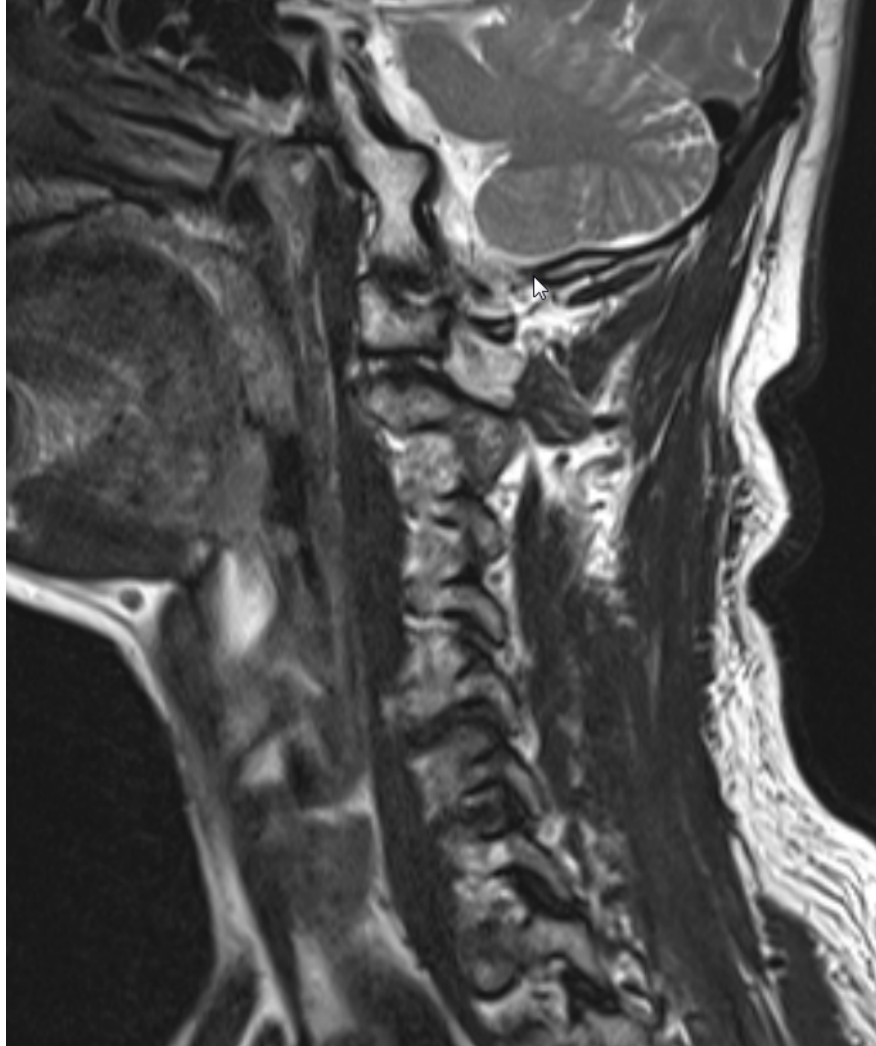
Chief complaint: PNP, Rt arm ~ elbow radiating pain  
NRS 8

Present illness: Occurred without any special trauma 1  
month ago

No neurologic deficit

# Pre OP MRI

## Rt foramen



- Diagnosis

Disc protrusion C567

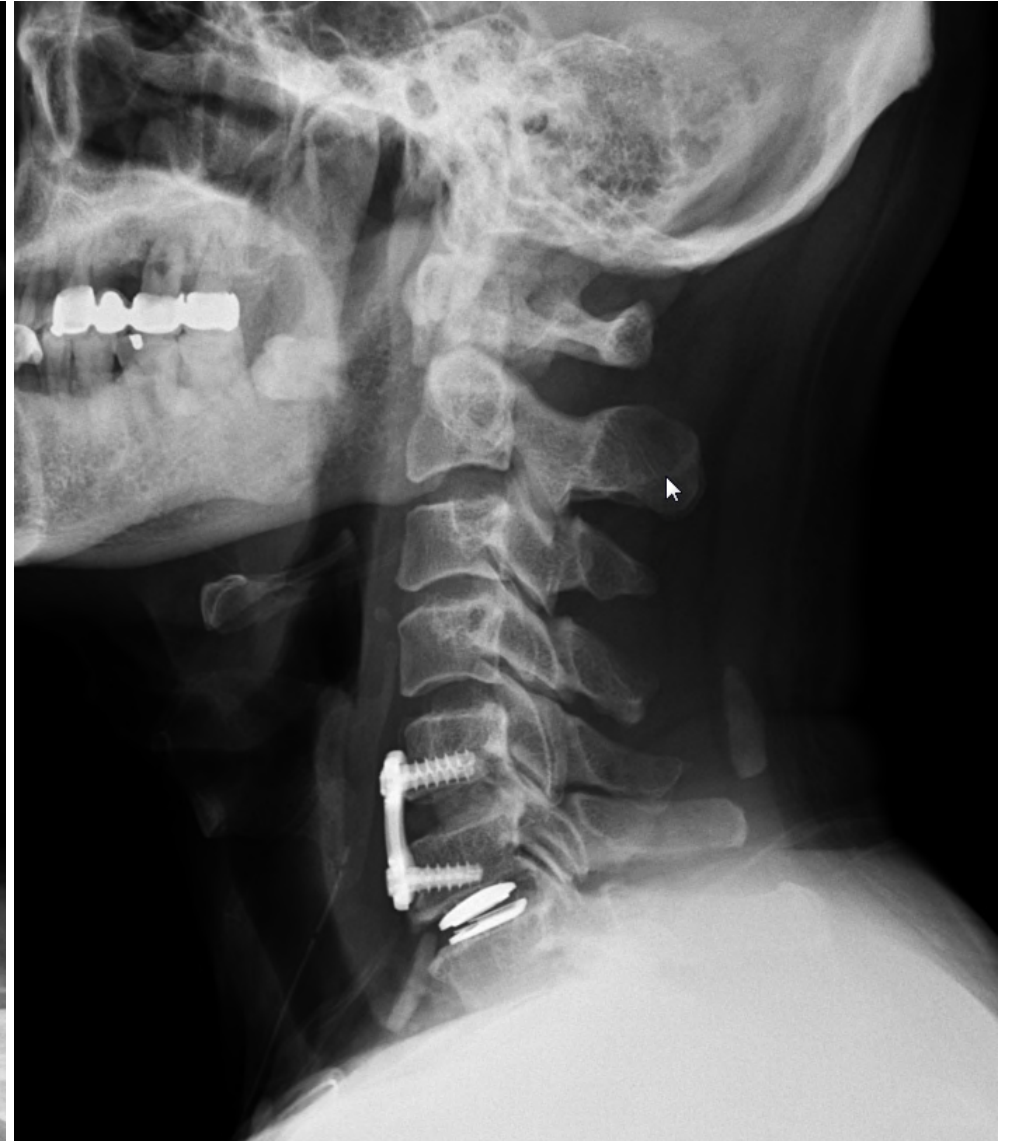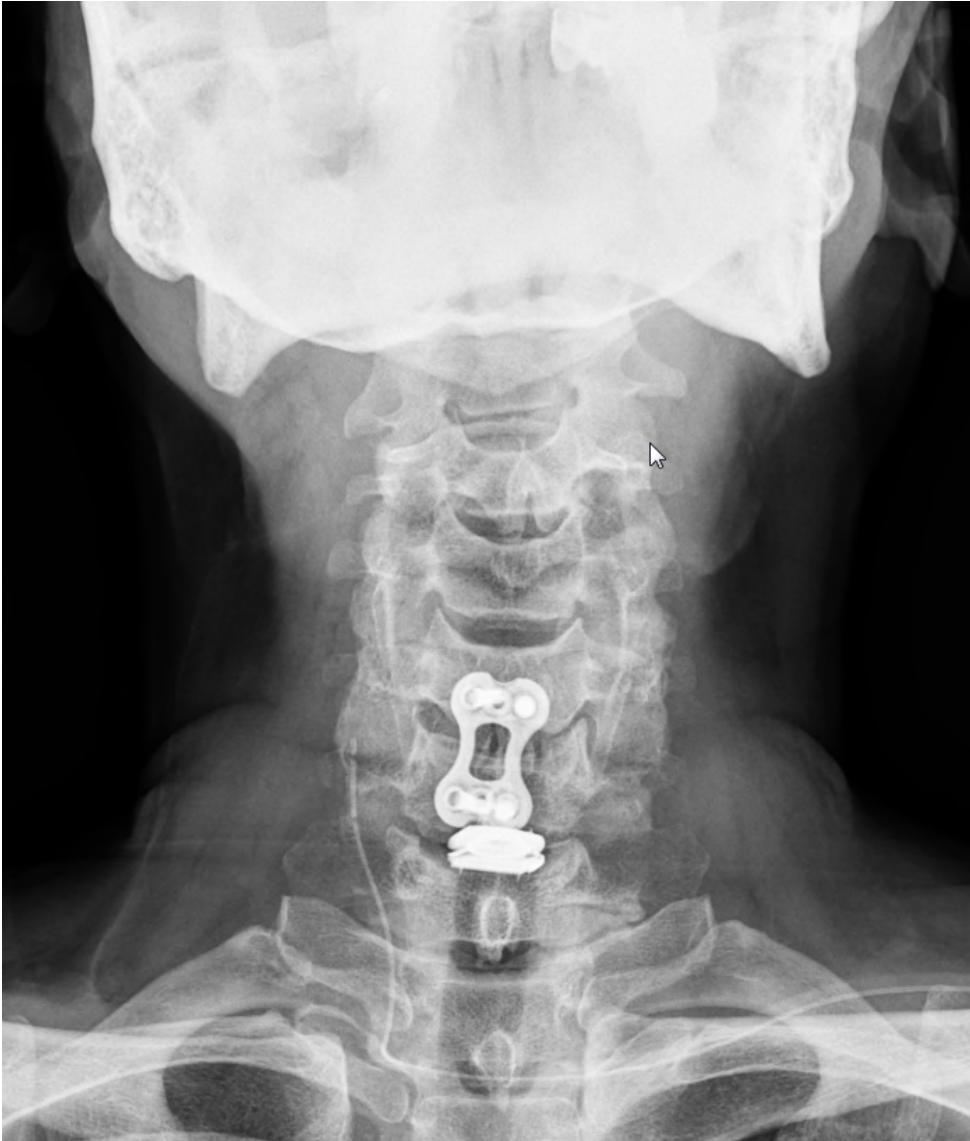Cord signal change C56

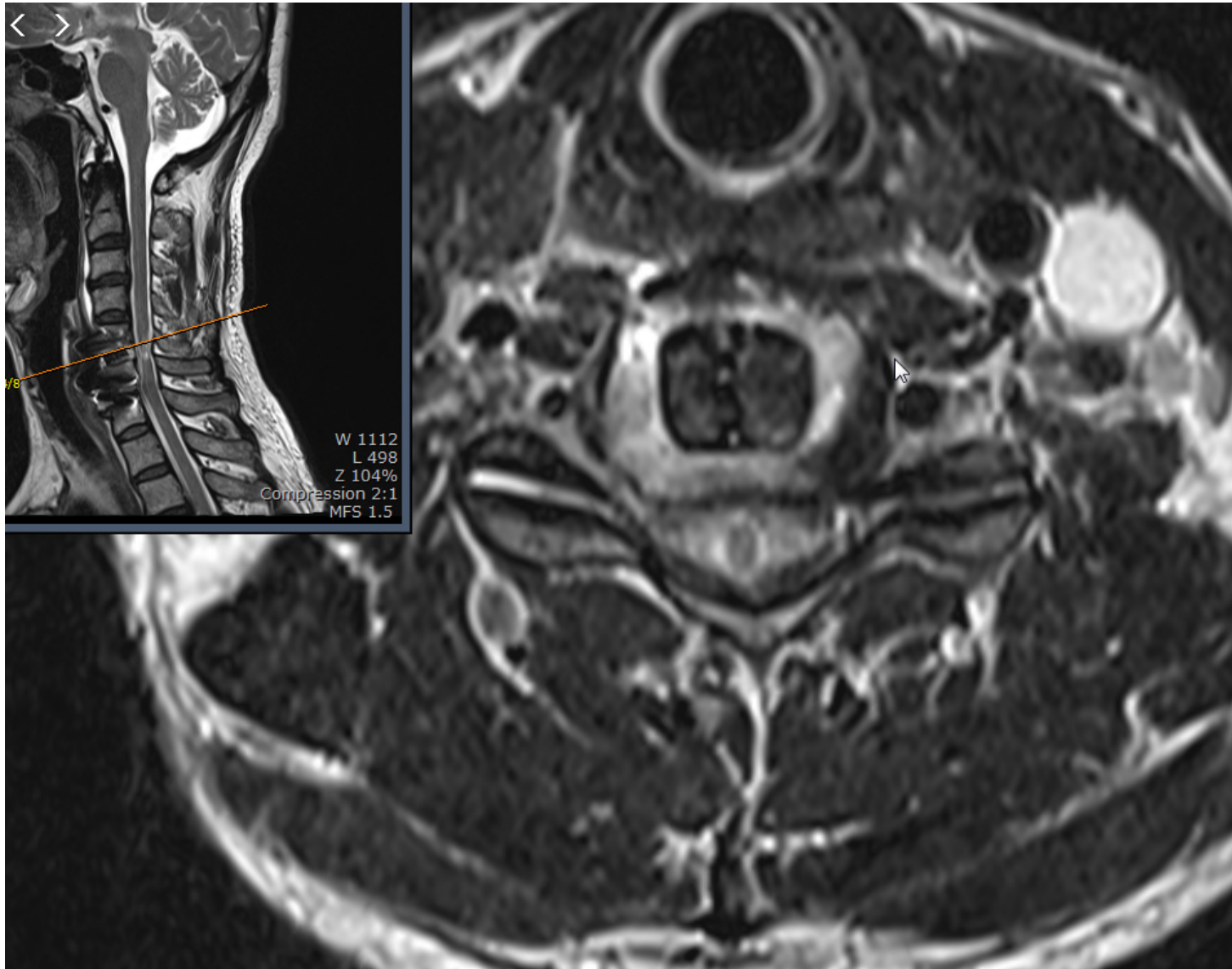
Foraminal stenosis C56 Rt

Foraminal stenosis C67 bilateral

## Plan

- ACDF C56 , ADR C67 (Rt FORA)





- POD #1
  - The numbness in my right arm got better, but I started having pain in my left shoulder and arm.
- 
- POD #9
  - After conservative treatment, left-side pain also improved.